

## Protocol of an Immediate Loading Procedure in Severe Mandibular Atrophy.

With the courtesy of Dr. Balan Igal D.M.D.

### A 79 year old patient – Non-smoker

#### Anamnesis:

- Controlled Hypertension
- Hypothyroidism,
- Mastectomy (15 years prior to the date of examination).

#### Principal Patient's Complaints:

- Impaired aesthetic,
- Difficulty in chewing due to loss of posterior teeth,
- Bad breath odor,
- Teeth mobility.

#### Intraoral examination:

- Severe bilateral alveolar bone loss – posterior mandible. (Fig.1)
- Reduced posterior occlusal support.
- Chronic generalized severe periodontitis.

#### Treatment Plan:

- Mandibular clearance. (Fig.2)
- Placement of four implants:
  - Two Cortical implants at the extraction sites;
  - Two tilted implants at the posterior area;
 Cortical implants are aggressively threaded implants that provide primary stability and bi-cortical anchoring (Fig3). These implants allow immediate loading due to their primary high stability. Cortical implants are provided with a smooth "Neck" surface (i.e. with no aggressive roughness). The smooth neck surface reduces the adherence of perio-pathogens thus reducing the development of inflammatory process around the neck area (i.e mucositis and peri-implantitis)
- The tilted implants are to be installed as distally as possible in order to shorten any possible extension and its resulting cantilever effect.
- These implants are also of the smooth neck surface type, for the same reasons as detailed above (Fig4).
- The implants would be immediately loaded and rehabilitated by a screws retained acrylic bridge, reinforced by a 3 mm induction welded titanium (grade 5) bar.
- The bridge to be is a screw retained type restoration, based on angle correcting multi unit abutments.

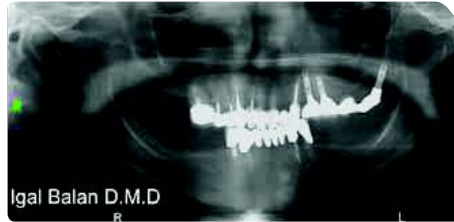

Fig.1 Panoramic X-Ray demonstrating extensive bone loss in the posterior mandible.

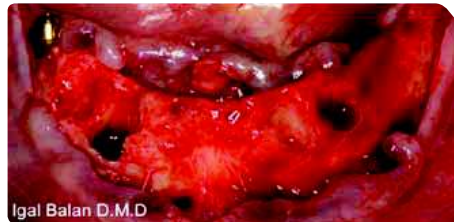


Fig.2 Post extraction site



Fig.3 Cortical implant (4X18 mm) with an aggressive thread for a better primary stability and with a smooth neck surface for reduction of bacterial adherence and inflammatory process development.

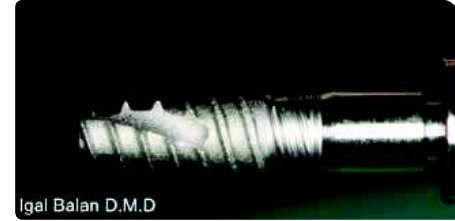


Fig. 4 TUFF Implant (37.5X11.5 mm) with a smooth neck surface for reducing bacteria accumulation and infection.

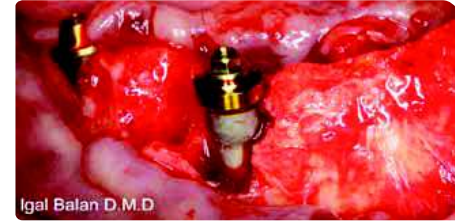


Fig.6 Straight Multi-Unit abutment mounted on the Cortical implant.

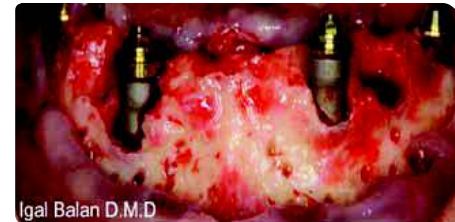

Fig.8 Four implants with Multi-Units showing the Decortication of the bone prior to bone grafting.

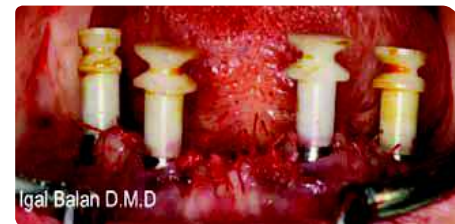

Fig.10 Snap-on Transfer for an easy impression taking using closed tray technique.

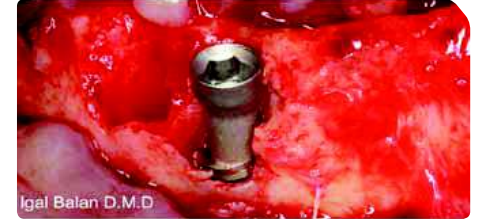


Fig.5 Cortical implant located in the extraction site of tooth 43. The Coronal area is left exposed due to bone loss.

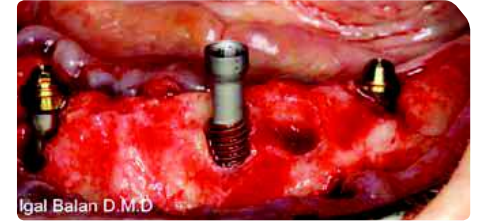

Fig.7 Cortical implant (4X20 mm) located in the extraction site of tooth 33.

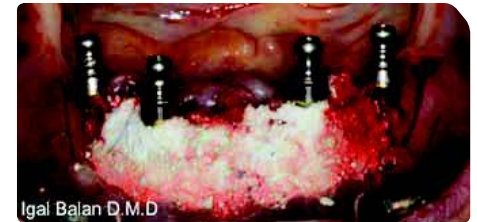

Fig.9 Bone augmentation using HA & Calcium sulfate bone graft.

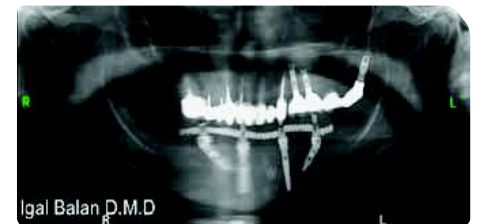

Fig.11 Post op. panoramic X-Ray, taken at the day of the operation.